

Review article

Watch out for neuromyelitis optica spectrum disorder onset or clinical relapse after COVID-19 vaccination: What neurologists need to know?

Sepideh Paybast^a, Ali Emami^a, Fatemeh Baghalha^b, Abdorreza Naser Moghadasi^{a,*}^a Multiple Sclerosis Research Center, Neuroscience Institute, Tehran University of Medical Sciences, Tehran, Iran^b Medical Librarian, Clinical Research Developmental Center, Emam Hossein Educational Hospital, Shahid Beheshti University of Medical Sciences, Tehran, Iran

ARTICLE INFO

Keywords:

MOGAD
AQP4
NMOSD
COVID-19 vaccines
SARS-CoV-2
Adverse effects

ABSTRACT

Introduction: The ongoing global COVID-19 pandemic has dramatically impacted our lives. We conducted this systematic review to investigate the safety of the COVID-19 vaccines in NMOSD patients.

Methods: We systematically searched PubMed, Scopus, Web of Science, and Embase from the beginning of the COVID-19 vaccination to March 1, 2022. Except for the letters, posters, and reviews, we included all related articles to answer two main questions. Our first question examined the occurrence of NMOSD onset as an adverse effect of the COVID-19 vaccine. Our second question investigated the safety of the COVID-19 vaccines in NMOSD patients.

Results: Out of 262 records, nine studies, including five studies for the first question and four studies for the second question, met the inclusion criteria. Out of the six patients with NMOSD onset after COVID-19 vaccination, five (83.3%) were female. The median time to NMOSD onset was 6.5 days, and the frequency of the COVID-19 vaccine type was identical in all patients. The most common presentation was longitudinally extensive transverse myelitis, significantly improved by pulse methylprednisolone with or without plasma exchange. The maintenance therapy was described only in three patients: rituximab (n=2) and azathioprine (n=1). Regarding the second question, out of 67 patients, 77.61% were female, with a mean age of 54.75 years old, a mean EDSS of 2.83, and a mean disease duration of 9.5 years. 77% reported at least one preexisting comorbidity. 88.05% were under treatment, most of which were rituximab and azathioprine. 98.50% received two doses of the COVID-19 vaccine. mRNA vaccines were the most commonly used vaccine (86.56%), which were well tolerated. No significant adverse event was reported, and local pain was the most frequently reported. 4.67% of the patients experienced a clinical relapse after a mean interval of 49.75 days, which was mainly mild to moderate in severity. Unfortunately, the data on the COVID-19 vaccines were missing.

Conclusion: The analysis suggests the safety profile of the COVID-19 vaccines. All NMOSD patients are strongly recommended to vaccinate for COVID-19. To maximize the effectiveness of the COVID-19 vaccines, further studies are needed to draw the best practice for vaccination.

1. Introduction

The ongoing global COVID-19 pandemic, caused by the Severe acute respiratory syndrome coronavirus 2 (SARS-CoV-2), has dramatically impacted our lives. Along with the respiratory symptoms, manifold neurological manifestations have been reported, associated with the direct viral invasion and/or over activation of the autoimmune responses (Collantes et al., 2021). In the meantime, COVID-19 vaccination has been implemented in many countries as the most productive strategy to control the pandemic. However, concerns are just beginning to

disclose regarding the neurological complications such as central nervous system (CNS) demyelinating events following COVID-19 vaccination (Goss et al., 2021). Another concern is the effectiveness of the COVID-19 vaccine in immunocompromised patients, which might challenge the timing of immunization (Goyal et al., 2015, Fiala et al., 2022).

Neuromyelitis Optica Spectrum Disorder (NMOSD) is a demyelinating autoimmune disease characterized by severe optic neuritis and longitudinally extensive transverse myelitis. Its prevalence ranges from approximately 0.5 to 10/100,000, with a higher prevalence in East

* Corresponding author.

E-mail address: abdorrezamoghadasi@gmail.com (A. Naser Moghadasi).<https://doi.org/10.1016/j.msard.2022.103960>

Received 18 April 2022; Received in revised form 22 May 2022; Accepted 9 June 2022

Available online 10 June 2022

2211-0348/© 2022 Elsevier B.V. All rights reserved.

Asian populations. In Up to 87% of NMOSD patients, the aquaporin-4 (AQP4) water channel is recognized as the significant antigen target. Up to 42% of seronegative patients harbor the myelin oligodendrocyte glycoprotein (MOG) antibody (Li et al., 2022; Velasco et al., 2021). Maintenance immunotherapy is strongly recommended in all patients regarding the disease's relapsing nature, the severity of attacks, and plausible incomplete recovery, leading to a risk of accumulating disability with each attack. Several immunosuppressive agents have been introduced as preventive treatments in NMOSD patients, of which anti-CD20 monoclonal antibody (rituximab) has successfully demonstrated favorable results (Velasco et al., 2021; Flanagan, 2019; Banerjee and Butcher, 2021).

There is some evidence that anti-CD20 antibodies exposure is associated with severe COVID-19 and lower anti-spike humoral immunity after COVID-19 vaccination (Schiaivetti et al., 2021; Barzegar et al., 2021; Levavi et al., 2021). Moreover, recent reports of the first manifestations of NMOSD following the recent exposure to the COVID-19 vaccine raised concerns about the COVID-19 vaccine safety (Caliskan et al., 2022; Fujikawa et al., 2021; Anamnart et al., 2021; Badrawi et al., 2021; Chen et al., 2021).

Given the limited data on the safety profile of the COVID-19 vaccines in NMOSD patients, the present study aimed to review the existing literature addressing the safety of the COVID-19 vaccines in NMOSD patients to provide a more comprehensive view of the importance of the most appropriate strategy in the management of the NMOSD patients in the COVID-19 era.

2. Material and methods

We designed a systematic review to answer two main questions relating to the safety and efficacy of the COVID-19 vaccines in patients with NMOSD. Our report was carried out under the Preferred Reporting Items for Systematic Reviews and Meta-Analysis (PRISMA) guidelines. Our first question examined the occurrence of early manifestations of NMOSD as an adverse effect of the COVID-19 vaccine. Our second question investigated the safety of the COVID-19 vaccines in NMOSD patients.

2.1. Search strategy

The search was carried out in four databases, including PubMed (n=15), Scopus (n=111), Web of Science (n=32), and Embase (n=32) from the beginning of the COVID-19 vaccination to March 1, 2022, for related published articles. The MeSH keywords (COVID-19 Vaccines, SARS-CoV-2 vaccines) AND (adverse effects) AND (MOGAD, AQP4, NMOSD) in title, abstract, and keywords were used. We assessed study inclusion based on the research questions. We included all cohorts, cross-sectional studies, case reports, and case series to review the safety and efficacy of COVID-19 vaccines in NMOSD patients. Articles written in English were all included.

Two authors independently screened the abstracts, and if deemed relevant, the full papers were subsequently reviewed. One independent reviewer focused on the role of COVID-19 vaccines in NMOSD manifestations. The second independent reviewer focused on the safety of the COVID-19 vaccine in NMOSD patients. We subsequently screened the full-text papers to decide which articles meet the inclusion criteria. The studies with the following features were excluded: (Collantes et al., 2021) studies focusing on general adverse effects of COVID-19 vaccination, (Goss et al., 2021) populations of other demyelinating disorders apart from NMOSD, (Goyal et al., 2015) pediatric population, (Fiala et al., 2022) the letters, posters, and reviews.

A meta-analysis and application of statistics were not possible given the nature of the studies and the heterogeneity of the reported outcomes.

3. Results

Searches of the databases and reference lists identified 262 articles, of which 125 studies were excluded after removing the duplicates (n=137) and reviewing the title/abstract (n=27). Of the remaining 27 articles, 18 were excluded for the following reasons: studies focusing on other demyelinating disorders, COVID-19 infection, and the pediatric population, studies with unavailable full-texts or insufficient data, non-English written studies, and a study with irrelevant outcomes (Fig. 1).

Eventually, nine full-text articles (73 patients) were included in this systematic review. Five studies (6 patients) were included for the first question, and four studies (67 patients) were included for the second question. Tables 1 and 2 summarize the studies on the NMOSD and COVID-19 vaccine.

3.1. Demographic characteristics

Of the six patients with NMOSD onset following recent exposure to COVID-19 vaccines, five (83.3%) were female, and one (16.7%) was male. The mean age of the patients was 39 years old. None reported pre-existing comorbidity except for the one (16.7%) with a past medical history of vitamin B12 deficiency (on replacement therapy).

The median interval between receiving the COVID-19 vaccine and the initial symptoms of NMOSD was 6.5 days. Four patients (66.6%) reported the initiation of symptoms after receiving the first dose of the vaccine. The primary implicated vaccines included messenger RNA (mRNA) (33.3%), viral vector (33.3%), and inactivated vaccines (33.3%).

3.2. Clinical characteristics

One patient (16.7%) experienced two demyelinating attacks in a month. Since all laboratory and radiological investigations were normal in the first attack, it was initially considered isolated optic neuritis associated with COVID-19 vaccination. However, following the second attack (transverse myelitis), subsequent investigations confirmed the diagnosis of NMOSD. Among the seven episodes, transverse myelitis was the most common presentation accounting for 57.14% of cases, two of which were classified as longitudinally extensive transverse myelitis (LETM) (28.57%). Brain stem syndrome represented the first clinical manifestations in two patients (28.57%). The attack was multiregional in one patient (16.7%), involving the brain stem and diencephalic structures.

3.3. Laboratory investigations

Five patients (83.3%) were AQP4-IgG seropositive. Serum evaluations for inflammatory, metabolic, infectious, and autoimmune immunologic markers were unrevealing in five patients (83.3%). However, positive antibodies for ANA, SSA, SSB, Ro-52, and P-ANCA were found in one patient (16.7%), leading to a diagnosis of AQP4-positive NMOSD with coexisting systemic autoimmunity. A cerebrospinal fluid (CSF) analysis revealed mononuclear leukocytes with slightly elevated protein in two patients (33.3%), and positive oligoclonal bands (OCB) restricted to the CSF in one patient (16.7%).

3.4. Treatments and outcomes

High-dose corticosteroids (5-7 gr intravenous methylprednisolone) were initially administered to all patients, followed by plasma exchange as an escalation therapy in three patients with severe attacks. The maintenance therapy was described only in three patients: rituximab (n=2) and azathioprine (n=1). A significant clinical improvement was achieved in all patients, and no subsequent relapse occurred during the follow-up.

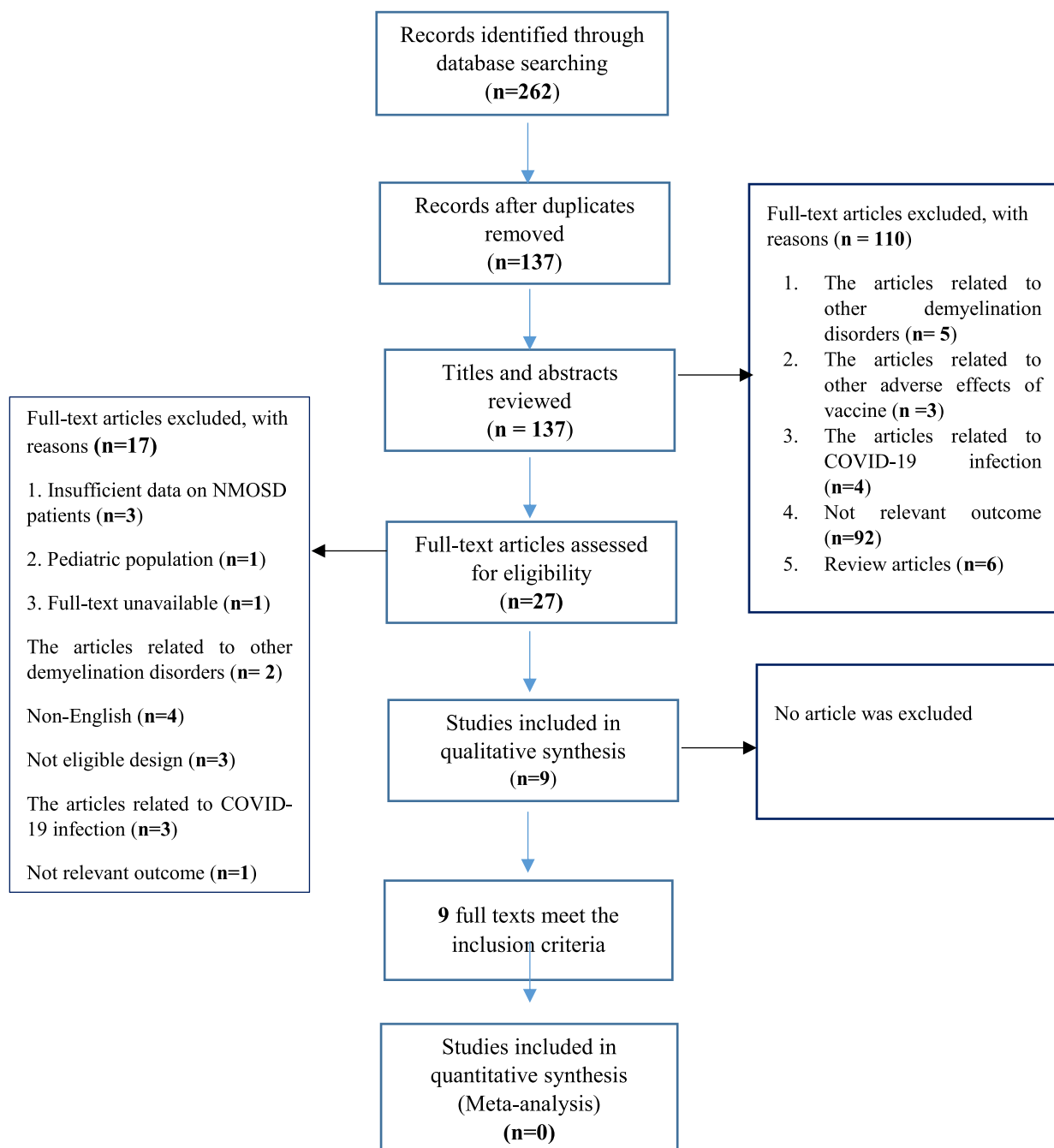


Fig. 1. Preferred Reporting Items for Systematic Reviews and Meta-analysis flow chart depicting the selection process of included studies.

3.5. Question 2:

The safety of the COVID-19 vaccines in patients with NMOSD.

3.6. Demographic and clinical characteristics

A total of 67 patients were evaluated, of whom 52 (77.61%) were female, with a mean age of 54.75 years old. In a cohort of 9 patients, seven patients (77.7%) reported at least one prior medical condition, of which hypertension was the most frequent. The mean disease duration of NMOSD was reported in two studies (9.5 years). The median Expanded Disability Status Scale (EDSS) was 2.83 in three studies. Fifty-nine patients (88.05%) were under treatment. The most commonly used disease-modifying treatment (DMTs) were rituximab (40.67%) and azathioprine (38.98%), respectively.

3.7. Safety of the COVID-19 vaccines

Sixty-six patients (98.50%) received two doses of the COVID-19 vaccine. The types of COVID-19 vaccines reported were mRNA vaccines (86.56%), inactivated vaccines (11.94%), and viral vector vaccines (1.49%).

The data on the interval between COVID-19 vaccination and infusible treatment in patients treated with infusible DMTs was missing. In addition, the data on the humoral response after the COVID-19 vaccination was missing in the literature. However, one study indicated a patient with a positive SARS-CoV-2 antibody response (8.28) who developed mild COVID-19 nine days after COVID-19 vaccination.

In terms of vaccine safety, three studies (66 patients) evaluated the safety of COVID-19 vaccines in NMOSD patients. While the mean follow-up of 2.5 months, 32% of the vaccine recipients did not report any

Table 1
the initial characteristics of patients with the first presentation of NMOSD following COVID-19 vaccination.

Author	Study design	Age	Sex	MRI findings	Specific Abs related to NMOSD	Laboratory investigations			NMOSD treatment		Vaccine type	Vaccine dose	Interval (days)	
						Routine lab data	Vasculitis W/U	CSF findings	Acute	Maintenance				
Caliskan et al. (2022)	Case report (n=1)	43	F	First attack: Right optic neuritis Second attack: myelitis	The first MRI was normal except for an enhancing hyperintense signal in the right optic nerve. Second MRI: Brain: gadolinium-enhancing lesion at the right peritrium and a non-contrast enhancing lesion at the left crus cerebri Cervical: a T2-hyperintense longitudinally extensive spinal cord lesion with patchy contrast enhancement in C1 to midthoracic.	AQP4: positive (1:320)	Normal	Normal	mononuclear leukocytes with slightly elevated protein, positive OCB	IVMP and P/E	Rituximab	mRNA BNT162b2 vaccine	Second (with an interval of 4 weeks)	First attack: 1 day Second attack: 31 days
Fujikawa et al. (2021)	Case report (n=1)	46	F	Sensory-motor myelitis (quadripareshtesia and paresis with urinary retention)	Brain: unremarkable Cervical: A longitudinally extensive C6-T2 hyper signal changes without enhancement	AQP4: negative	Normal	Negative	Normal	IVMP	Tapering dose of prednisolone	SARS-CoV-2 mRNA-1273 vaccine	First	Two days
Anamart et al. (2021)	Case report (n=2)	26	F	Partial myelitis (left hemiparesis evolving to the right side and trunk)	Brain: unremarkable Cervical: focal intramedullary hyperintense signal and heterogeneous enhancement of left-sided cervical cord at C4-C5 levels	AQP4: positive (titer 1:320)	Normal	Normal	Normal	IVMP and P/E	Tapering dose of prednisolone and Rituximab	CoronaVac, Sinovac®	First	1Tendays
		46	F	Partial myelitis (right hemiparesis and paresthesia evolving to the trunk)	Brain: abnormal T2 hyperintense signals and corresponding T1 hypointense signals with inhomogeneous gadolinium enhancement at the right lateral aspect of the medulla and subependymal periventricular area along the right lateral ventricle Cervical: focal intramedullary T2 hyperintense signal with the heterogeneous enhancement of right-sided cervical cord at C2-C3 levels	AQP4: positive (titer 1:320)	Normal	Normal	Normal	IVMP	Tapering dose of oral prednisolone and Azathioprine	ChAdOx1 n CoV-19 (Oxford–AstraZeneca) vaccine	First	Ten days
Badrawi et al. (2021)	Case report (n=1)	34	M	acute confusional state and ataxia	Brain: patchy, hyperintense signal along the ependymal surface of the lateral, third, and fourth ventricles, thalamus, corpus callosum, and optic chiasma on FLAIR sequence Cervical: unremarkable	AQP4: positive (titer 1:40)	Normal	Lymphocytosis and mildly raised protein. other studied variables were negative	Normal	P/E	NA	Sputnik V COVID-19 vaccine	Second	21 days
Chen et al. (2021)	Case report (n=1)	Middle-aged	F	Persistent nausea and vomiting for more than a month, followed by ataxia	Brain: hyperintense signal along the area postrema and bilateral hypothalamus on FLAIR sequence Cervical: unremarkable	AQP4: positive	Leucopenia (2.36 × 10 ⁹ /L)	Lymphocytosis. Other studied variables were normal	Positive Ab for ANA, SSA, SSB, Ro-52, and p-ANCA	IVMP	NA	Inactivated virus vaccine	First	Three days

Table 2
The efficacy and safety of COVID-19 vaccination in NMOSD patients.

Author	Study design	Disease duration (years)	Age (years)	Sex	Median EDSS	Comorbidity	DMT	Vaccine type	Vaccine dose	SARS Cov2 Ab titer	COVID-19 infection after vaccination	Adverse events of vaccination	Disease activity after vaccination	Mean follow up
Jovicevic et al. (2022)	Cohort(n=9)	11.1± 6.3	54.3 ± 10.3	F (66.6%)	4.0(IQR = 3.75)	At least one comorbidity (77.7%)	AZA (77.7%) Inebilizumab (11.1%) None (11.1%)	Sinopharm (88.8%), Pfizer-BioNTech (11.1%)	2	NA	None	Local pain (11.1%)	Negative	4.3 months
Fragoso et al. (2022)	Case series (n=9,NMOSD (n=1))	8	62	F	NA	NA	AZA	AZD1222	1	NA	NA	Unspecific	Left optic neuritis, a week after vaccination	Three weeks (Complete resolution of the symptoms)
Januel et al. (2021)	Case series (n=18, NMOSD (n=1))	NA	56	F	2.5	None	Rituximab (5 cycles before vaccination)	BNT162b2	2	8.26	Nine days after vaccination: Not hospitalized, limitation on activities	NA	NA	NA
Dinoto et al. (2022)	Retrospective multicenter study (MOGAD, 30;AQP4-IgG+NMOSD, 26)(n=56)	NA	47 (23–84)	F (79%)	2	NA	No treatment (14.3%),AZA (26.8%),MMF (1.8%),Rituximab (41.4%), Tocilizumab (3.6%), Eculizumab (1.8%),Prednisone (5.4%), Prednisone + IVIG (1.8%), Prednisone+ MTX (1.8%),Weekly PLEX(1.8%)	BNT162b2-Pfizer-BioNTech (75%), mRNA-1273-Moderna (25%)	2	NA	NA	First vaccine: No side effects (36%),Local pain (41%),Fever (2%),Fatigue (5%), nausea (2%) Second vaccine: No side effects(28%), Local pain(42%), Fever 6, (11%) Two or more 10 (19%)	Three patients (5%) (myelitis, optic neuritis, and cerebellar ataxia) after a median of 85 (10–97) days	5 (1–8) months

adverse events. Meanwhile, all adverse reactions reported were mild to moderate in severity, among which self-resolved local pain was the most frequent. It should be noted that the laboratory safety testing was not stated in the data obtained in our review.

Regarding the clinical relapse, a total of four relapses (4.67%) were demonstrated in patients without a previous history of clinical relapse, triggered by infections or vaccinations, after a mean interval of 49.75 days after receiving the second dose of the COVID-19 vaccine. Three patients (75%) were female with a mean age of 53.6 years with AQP4-IgG positivity and a 61-year-old man (25%) with MOG-IgG positivity. Two patients (50%) were untreated, and the other two patients were treated with rituximab and azathioprine. The relapses comprised optic neuritis (50%) and myelitis (50%), treated with intravenous methylprednisolone. Except for the one (25%) with severe myelitis, all patients had a significant clinical recovery. However, the maintenance therapy adjustment details could not be found in the published articles.

4. Discussion

To the best of our knowledge, this is the most comprehensive systematic review which investigates the role of COVID-19 vaccination in the development of NMOSD and the safety and efficacy of the COVID-19 vaccination in NMOSD patients. In many publications, the challenges associated with COVID-19 immunization have been reported in the MS population. Additionally, the only reported case report and systematic review included a limited number of patients.

In this systematic review, we identified that six patients developed the initial manifestations of NMOSD following recent exposure to the COVID-19 vaccines, which raised the possibility that these vaccines might induce NMOSD manifestations or accelerate the transition from subclinical to clinical disease. Notably, vaccination has been previously implicated as a trigger of other central nervous systems (CNS) demyelinating syndromes. However, its association with NMOSD onset is vague (Akaishi et al., 2020; Langer-Gould et al., 2014).

The previous reports have revealed that SARS-CoV-2 might affect the CNS via autoimmune response combined with endothelial dysfunction, leading to a clinical picture or imaging compatible with CNS demyelinating syndrome as NMOSD (Ghosh et al., 2021; Abboud et al., 2020). Consequently, the COVID-19 vaccines might have a similar effect in accelerating the onset of overt CNS demyelination. An increased immune response following vaccination could boost the immune response to self-antigens, which may partly explain the development of autoimmune disorders after vaccination (Langer-Gould et al., 2014; Zrzavy et al., 2019).

Vaccine-induced immunity depends on a set of neutralizing or anti-toxic antibodies, CD8+ T cells, CD4+ T cells and corresponding cytokines, and antigen-presenting cells (APCs) of the innate immune system, which varies according to the type of vaccine administration, kind of vaccine, and adjuvant part of the vaccines (Zrzavy et al., 2019). By the end of February 2021, 256 COVID-19 vaccine candidates have been developed based on different approaches, including live-attenuated or inactivated vaccines (8.2%), non-replicating viral vector vaccines (13.3%), replicating viral vector vaccines (9.8%), recombinant protein-based vaccines (protein subunit vaccines (35.9%), virus-like particles (VLP)), and nucleic acid vaccines (DNA- (10.2%) and mRNA-based (12.1%) vaccines) (Golshani and Hrdý, 2022). The types of COVID-19 vaccines reported were mRNA vaccines (86.56%), inactivated vaccines (11.94%), and viral vector vaccines (1.49%). While the frequency of the COVID-19 vaccine type was identical in patients with initial NMOSD manifestations following COVID-19 vaccination, mRNA vaccines were the most commonly used vaccine among the known NMOSD patients (86.56%) (Mealy et al., 2018).

Some evidence suggests that vaccination might play a role in the onset or relapse of NMOSD. Interestingly, NMOSD onset in temporal association with qHPV-vac vaccines has been the most frequent report, mainly after a mean interval of 4-5 months (Menge et al., 2012).

Although uncertain, the upregulation of the adaptive and innate immune system leading to a bystander lymphocyte activation has been considered the most likely contributing mechanism (Zrzavy et al., 2019; Mealy et al., 2018; Menge et al., 2012). In terms of relapse, a recent study on ninety patients revealed a higher risk of vaccination-associated relapse in untreated patients. While the patients treated with immunosuppressive therapy had lower annualized relapse rates than unvaccinated patients. In addition, the risk of clinical activity was observed up to 90 days, particularly in the first 30 (Mealy et al., 2018). Bearing this concern, an anonymous survey on the safety and tolerability of the COVID-19 vaccines in 438 patients with rare CNS immunological disease (including 341 patients with NMOSD) revealed that seventy-seven participants (16.7%) reported new or worsening neurological symptoms, of whom 17.8% needed medical treatment. The sensory symptoms and increased pain were the most frequently reported neurologic adverse events, occurring mainly in the first week after vaccination and resolving within three days. Moreover, consistent with previous reports, patients treated with immunotherapies, predominantly those receiving anti-B-cell agents, had the lowest chance for neurological symptoms (Lotan et al., 2021).

In this systematic review, to warrant a strong relationship between vaccine and NMOSD, we included patients with initial manifestations of NMOSD within 30 days after vaccination, according to the World Health Organization (WHO) guideline on adverse events following vaccine immunization (Organization, 2018). In line with previous reports, the median time to NMOSD onset was 6.5 days, and the most common presentation was transverse myelitis (57.14%) (Caliskan et al., 2022; Fujikawa et al., 2021; Anamnart et al., 2021). However, it is still hard to say whether the interaction between COVID-19 vaccination and autoimmunity is natural or coincidental. The pathogenic antibody might exist many years before the disease onset, and vaccination is theoretically more likely to trigger the first attack, as it is impossible to start immunosuppressant before the first attack merely because of a positive antibody. In terms of COVID-19 vaccines safety, our results disclosed that the COVID-19 vaccines were well-tolerated in NMOSD patients. Out of 67 patients, only four patients (4.67%) reported clinical relapse, of whom two were untreated. Accordingly, COVID-19 vaccination is not likely to trigger a relapse in patients with an established diagnosis who have been stable on immunosuppressants for a particular time before immunization.

Unfortunately, the data on the vaccine's efficacy was insufficient, and it was not possible to assess the level of vaccine-induced immunity in these patients. Further, the last infusion of infusible DMTs and vaccination intervals were not reported in the obtained articles.

NMOSD treatments used for the management of acute attacks (methylprednisolone) and prevention of attacks (prednisone, azathioprine, mycophenolate mofetil, anti-B-cell antibodies, anti-IL-6 receptor monoclonal antibodies) reduce the immune system (Velasco et al., 2021; Flanagan, 2019). However, little is known about the outcome of COVID-19 in patients with NMOSD or MOGAD. A recent meta-analysis revealed a 12% prevalence of COVID-19 in NMOSD patients with a 33.7% hospitalization rate. They suggested that patients treated with rituximab and those with underlying comorbidity were more susceptible to developing COVID-19 (Barzegar et al., 2021).

On the other hand, several studies have shown a decreased level of anti-SARS-CoV-2 IgG and vaccine efficacy in patients treated with rituximab (Golshani and Hrdý, 2022; Baker et al., 2020; Baker et al., 2021; Toscano et al., 2021). Given the importance of continuing treatment in NMOSD patients to prevent the potentially life-threatening attacks and the possibility of reduced humoral response to the COVID-19 vaccines in patients treated with immunosuppressive DMTs, it is paramount to assume the best practice to vaccinate NMOSD patients (Abboud et al., 2016; Abboud et al., 2020; Croce et al., 2017; Papp et al., 2019). While some authors suggest considering a time interval of 4-6 months before and after vaccination to overcome the rapid and prolonged B-cell depletion and reduced humoral immune responsiveness by anti-B-cell

antibodies, others recommend one- and three-month time window before and after vaccination. Likewise, steroids should be temporarily delayed from the time of vaccination, and if they are urgently needed, COVID-19 vaccination should be postponed for at least four weeks (Toscano et al., 2021; Papp et al., 2019; Ferretti et al., 2021; Centonze et al., 2021).

Taking all into account, it can be concluded that since live-attenuated vaccines are contraindicated in immunocompromised patients, they have not been used in any of the patients. Moreover, while we found no particular safety concerns related to the approved COVID-19 vaccines in patients with NMOSD, their safety has yet to be determined. A rate of 4.67% of post-vaccination relapse was consistent with the results in the MS population (Toscano et al., 2021), which supports the benefits of COVID-19 vaccination on the risk of relapse. As a result, the administration of COVID-19 vaccines is strongly recommended for all NMOSD patients, and it is considered safe. To maximize the effectiveness of the COVID-19 vaccines, optimizing the timing to start a new DMT or infuse the DMTs in known cases of NMOSD is highly recommended. However, since the data on the time interval between vaccination and immunosuppressant infusion was missing in the current studies, it was not possible to truly estimate the best hesitation period after immunosuppressant infusion to receive COVID-19 vaccines.

Our study has some limitations. First, our study's small sample size, mainly the case report/ series, does not represent the NMOSD population. Second, the efficacy of the COVID-19 vaccines was not evaluated in most studies. Therefore, we could not determine the rate of COVID-19 infection and the severity of the disease before and after vaccination. Third, the majority of patients were treated with rituximab and azathioprine. Thus, we could not draw any conclusion on the impact of COVID vaccines on other DMTs. Fourth, the laboratory safety profile of the vaccines was missing, which might confound the proper interpretation of COVID-19 vaccines safety.

5. Conclusion

Our systematic review demonstrated six cases of NMOSD onset following recent exposure to COVID-19 vaccines. According to our results, the COVID-19 vaccines were well tolerated in NMOSD patients. 4.67% of the patients experienced clinical relapse after vaccination, mainly mild to moderate in severity. Unfortunately, the data on the efficacy of the vaccines were missing. Further studies are needed to determine the effectiveness of all types of COVID-19 vaccines in NMOSD patients treated with different kinds of DMTs to recommend the best guideline on the timeline of vaccination for those receiving immunosuppressive DMTs.

Funding

The authors have not declared a specific grant for this research from any funding agency.

Declaration of Competing Interest

None declared.

References

- Abboud, H, Abboud, FZ, Kharbouch, H, Arkha, Y, El Abbadi, N, El Ouahabi, A., 2020. COVID-19 and SARS-Cov-2 infection: pathophysiology and clinical effects on the nervous system. *World Neurosurg.* 140, 49–53.
- Abboud, H, Petrak, A, Mealy, M, Sasidharan, S, Siddique, L, Levy, M., 2016. Treatment of acute relapses in neuromyelitis optica: steroids alone versus steroids plus plasma exchange. *Mult. Scler. J.* 22 (2), 185–192.
- Abboud, H, Zheng, C, Kar, I, Chen, CK, Sau, C, Serra, A., 2020. Current and emerging therapeutics for neuromyelitis optica spectrum disorder: relevance to the COVID-19 pandemic. *Multiple Sclerosis Relat. Disord.* 44, 102249.
- Akaishi, T, Takahashi, T, Fujihara, K, Misu, T, Abe, M, Ishii, T, et al., 2020. Risk factors of attacks in neuromyelitis optica spectrum disorders. *J. Neuroimmunol.* 343, 577236.

- Anamart, C, Tisavipat, N, Owattanapanich, W, Apiwattanakul, M, Savangned, P, Prayoonwivat, N, et al., 2021. Newly diagnosed neuromyelitis optica spectrum disorders following vaccination: case report and systematic review. *Mult. Scler. Relat. Disord.*, 103414
- Badrawi, N, Kumar, N, Albastaki, U., 2021. Post COVID-19 vaccination neuromyelitis optica spectrum disorder: case report & MRI findings. *Radiol. Case Rep.* 16 (12), 3864–3867.
- Baker, D, Roberts, C, Pryce, G, Kang, A, Marta, M, Reyes, S, et al., 2020. COVID-19 vaccine-readiness for anti-CD20-depleting therapy in autoimmune diseases. *Clin. Exp. Immunol.* 202 (2), 149–161.
- Baker, D, MacDougall, A, Kang, AS, Schmierer, K, Giovannoni, G, Dobson, R., 2021. Seroconversion following COVID-19 vaccination: can we optimize protective response in CD20-treated individuals? *Clin. Exp. Immunol.*
- Banerjee, S, Butcher, R., 2021. Rituximab for the treatment of neuromyelitis optica spectrum disorder. *Can. J. Health Technol.* 1 (2).
- Barzegar, M, Mirmosayyeb, O, Ebrahimi, N, Bagherieh, S, Afshari-Safavi, A, Hosseinebadi, AM, et al., 2021. COVID-19 susceptibility and outcomes among patients with neuromyelitis optica spectrum disorder (NMOSD): a systematic review and meta-analysis. *Mult. Scler. Relat. Disord.*, 103359
- Caliskan, I., Bulus, E., Afsar, N., Altintas, A., 2022. A case with new-onset neuromyelitis optica spectrum disorder following COVID-19 mRNA BNT162b2 vaccination. *Neurologist.*
- Centonze, D, Rocca, MA, Gasperini, C, Kappos, L, Hartung, H-P, Magyari, M, et al., 2021. Disease-modifying therapies and SARS-CoV-2 vaccination in multiple sclerosis: an expert consensus. *J. Neurol.* 268 (11), 3961–3968.
- Chen, S, Fan, XR, He, S, Zhang, JW, Li, SJ., 2021. Watch out for neuromyelitis optica spectrum disorder after inactivated virus vaccination for COVID-19. *Neurol. Sci.* 42 (9), 3537–3539.
- Collantes, MEV, Espiritu, AI, Sy, MCC, Anlacan, VMM, Jamora, RDG., 2021. Neurological manifestations in COVID-19 infection: a systematic review and meta-analysis. *Can. J. Neurol. Sci.* 48 (1), 66–76.
- Croce, E, Hatz, C, Jonker, EF, Visser, L, Jaeger, VK, Bühler, S., 2017. Safety of live vaccinations on immunosuppressive therapy in patients with immune-mediated inflammatory diseases, solid organ transplantation or after bone-marrow transplantation—a systematic review of randomized trials, observational studies and case reports. *Vaccine* 35 (9), 1216–1226.
- Dinoto, A, Sechi, E, Ferrari, S, Gajofatto, A, Orlandi, R, Solla, P, et al., 2022. Risk of disease relapse following COVID-19 vaccination in patients with AQP4-IgG-positive NMOSD and MOGAD. *Mult. Scler. Relat. Disord.* 58, 103424.
- Ferretti, F, Cannatelli, R, Benucci, M, Carmagnola, S, Clementi, E, Danelli, P, et al., 2021. How to manage COVID-19 vaccination in immune-mediated inflammatory diseases: an expert opinion by IMIDs study group. *Front. Immunol.* 12, 1206.
- Fiala, C, Rotstein, D, Pasic, MD., 2022. Pathobiology, diagnosis, and current biomarkers in neuromyelitis optica spectrum disorders. *J. Appl. Lab. Med.* 7 (1), 305–310.
- Flanagan, EP., 2019. Neuromyelitis optica spectrum disorder and other non-multiple sclerosis central nervous system inflammatory diseases. *Continuum* 25 (3), 815–844.
- Fragoso, YD, Gomes, S, Gonçalves, MVM, Junior, EM, de Oliveira, BES, Rocha, CF, et al., 2022. New relapse of multiple sclerosis and neuromyelitis optica as a potential adverse event of AstraZeneca AZD1222 vaccination for COVID-19. *Mult. Scler. Relat. Disord.* 57, 103321.
- Fujikawa, P, Shah, FA, Braford, M, Patel, K, Madey, J., 2021. Neuromyelitis optica in a healthy female after severe acute respiratory syndrome coronavirus 2 mRNA-1273 vaccine. *Cureus* 13 (9).
- Ghosh, R, De, K, Roy, D, Mandal, A, Biswas, S, Biswas, S, et al., 2021. A case of area postrema variant of neuromyelitis optica spectrum disorder following SARS-CoV-2 infection. *J. Neuroimmunol.* 350, 577439.
- Golshani, M, Hrdý, J., 2022. Multiple sclerosis patients and disease modifying therapies: impact on immune responses against COVID-19 and SARS-CoV-2 vaccination. *Vaccines* 10 (2), 279.
- Goss, AL, Samudralwar, RD, Das, RR, Nath, A., 2021. ANA investigates neurological complications of COVID-19 vaccines. *Ann. Neurol.* 89 (5), 856.
- Goyal, A, Goyal, K, Merola, JF., 2015. Screening and vaccinations in patients requiring systemic immunosuppression: an update for dermatologists. *Am. J. Clin. Dermatol.* 16 (3), 179–195.
- Januel, E, De Seze, J, Vermersch, P, Maillart, E, Bourre, B, Pique, J, et al., 2021. Post-vaccine COVID-19 in patients with multiple sclerosis or neuromyelitis optica. *Mult. Scler. J.*, 13524585211049737
- Jovicevic, V, Ivanovic, J, Andabaka, M, Tamas, O, Veselinovic, N, Momcilovic, N, et al., 2022. COVID-19 and vaccination against SARS-CoV-2 in patients with Neuromyelitis optica spectrum disorders. *Mult. Scler. Relat. Disord.* 57, 103320.
- Langer-Gould, A, Qian, L, Tartof, SY, Brara, SM, Jacobsen, SJ, Beaber, BE, et al., 2014. Vaccines and the risk of multiple sclerosis and other central nervous system demyelinating diseases. *JAMA Neurol.* 71 (12), 1506–1513.
- Levavi, H, Lancman, G, Gabrilove, J., 2021. Impact of rituximab on COVID-19 outcomes. *Ann. Hematol.* 100 (11), 2805–2812.
- Li, Y, Liu, X, Wang, J, Pan, C, Tang, Z., 2022. Clinical features and imaging findings of myelin oligodendrocyte glycoprotein-IgG-associated disorder (MOGAD). *Front. Aging Neurosci.* 14.
- Lotan, I, Romanow, G, Levy, M., 2021. Patient-reported safety and tolerability of the COVID-19 vaccines in persons with rare neuroimmunological diseases. *Mult. Scler. Relat. Disord.* 55, 103189.
- Mealy, MA, Cook, LJ, Pache, F, Velez, DL, Borisow, N, Becker, D, et al., 2018. Vaccines and the association with relapses in patients with neuromyelitis optica spectrum disorder. *Mult. Scler. Relat. Disord.* 23, 78–82.

- Menge, T, Cree, B, Saleh, A, Waterboer, T, Berthele, A, Kalluri, SR, et al., 2012. Neuromyelitis optica following human papillomavirus vaccination. *Neurology* 79 (3), 285–287.
- Organization WH. Causality assessment of an adverse event following immunization (AEFI): user manual for the revised WHO classification. 2018.
- Papp, KA, Haraoui, B, Kumar, D, Marshall, JK, Bissonnette, R, Bitton, A, et al., 2019. Vaccination guidelines for patients with immune-mediated disorders on immunosuppressive therapies. *J. Cutan. Med. Surg.* 23 (1), 50–74.
- Schiavetti, I, Ponzano, M, Signori, A, Bovis, F, Carmisciano, L, Sormani, MP., 2021. Severe outcomes of COVID-19 among patients with multiple sclerosis under anti-CD-20 therapies: a systematic review and meta-analysis. *Mult. Scler. Relat. Disord.*, 103358
- Toscano, S, Chisari, CG, Patti, F, 2021. Multiple sclerosis, COVID-19 and vaccines: making the point. *Neurol. Ther.* 10 (2), 627–649.
- Velasco, M, Zarco, LA, Agudelo-Arrieta, M, Torres-Camacho, I, Garcia-Cifuentes, E, Muñoz, O., 2021. Effectiveness of treatments in Neuromyelitis optica to modify the course of disease in adult patients. Systematic review of literature. *Mult. Scler. Relat. Disord.* 50, 102869.
- Zrzavy, T, Kollaritsch, H, Rommer, PS, Boxberger, N, Loebermann, M, Wimmer, I, et al., 2019. Vaccination in multiple sclerosis: friend or foe? *Front. Immunol.* 1883.